

## A case of cholestasis caused by *Fasciola hepatica* diagnosed with endosonography: "Sometimes seeing might not be enough, watching is required"

Endosonografi ile tanı konulan *Fasciola hepatica*'nın neden olduğu kolestaz vakası: 'Bazen görmek yeterli olmayabilir, izlemek gerekir'

İD Bilger ÇAVUŞ, İD Filiz AKYÜZ, İD Sabahattin KAYMAKOĞLU

Department of Internal Medicine, Division of Gastroenterology, Istanbul University, Istanbul School of Medicine, Istanbul

The most important causative factor of fasciolosis, one of the parasitic diseases of the liver, is the trematode *Fasciola hepatica*. Although ultrasonography and magnetic resonance imaging are the primarily preferred imaging methods for the diagnosis of *Fasciola hepatica* infection, which can be observed under different clinical conditions, endosonography can be used to address the diagnostic difficulties experienced with these methods. We describe a case of a patient with cholestasis caused by *Fasciola hepatica* that was diagnosed by endosonography.

**Keywords:** Endosonography, fasciolosis, cholestasis

Karaciğerin paraziter hastalıklarından biri olan fasioliyazisin en önemli etkeni bir trematod olan *Fasciola hepatica*'dır. Farklı klinikler ile ortaya çıkabilen *Fasciola hepatica*'nın tanısında ultrasonografi ve magnetik rezonans görüntüleme ilk tercih edilen görüntüleme yöntemleri olmakla birlikte, bu yöntemlerle yaşanan tanısal zorluklarda endosonografi ile çözüm üretilebilmektedir. *Fasciola hepatica*'nın neden olduğu kolestaz tablosunda endosonografi ile tanıya ulaştığımız bir olguyu sunduk.

**Anahtar kelimeler:** Endosonografi, fasioliyazis, kolestaz

### INTRODUCTION

Fasciolosis is a zoonotic infection that affects approximately 50 million people and poses a risk for 180 million people throughout the world, thus constituting an important global public health issue (1). Although ruminants such as sheep, goat, and buffalo are the definite hosts for *Fasciola hepatica* (*F. hepatica*), human beings coincidentally become hosts due to the consumption of water or raw vegetables contaminated with metacercaria (2). Migration of larvae from the bowel to the liver and biliary tracts in humans leads to acute and chronic stages of the disease. During these stages, patients with findings of fever with an unknown etiology, biliary colic and cholangitis, and concomitant eosinophilia should be primarily suspected in the clinical assessment for the diagnosis of the disease. In patients suspected to have fasciolosis, the diagnosis is established later on based on the existence of eggs in stool, positive serology in serum and stool samples, and the findings of the imaging methods (3,4).

### CASE REPORT

A 28-year-old female patient visited the emergency polyclinic with complaints of weakness, yellow eyes, and abdominal pain. The patient already had weakness for approximately 1 year and had received treatment for iron deficiency anemia. She has had intermittent complaints of abdominal pain for 1 year, and calculi measuring 3–4 mm in size were observed in her gallbladder in the USG performed during that period.

However, her epigastric pain and pain in the right upper quadrant became particularly severe in recent months along with the development of yellow eyes, due to which she visited the emergency polyclinic. Physical examination performed in the polyclinic revealed good general condition, as she was conscious, cooperative, and oriented. However, her skin and sclerae revealed symptoms of icterus. Furthermore, the patient was normotensive and showed grade 2/6 systolic murmurs in all foci in her cardiac examination. Her body temperature was 37.6°C, and there were no pathological findings in the evaluation of her respiratory system. Abdominal examination revealed sensitivity upon palpation in the right upper quadrant and the epigastric area. Laboratory analyses of her complete blood count showed the following results: white blood cells 13,800 mm<sup>3</sup>, neutrophils 13,100 mm<sup>3</sup>, eosinophils 100 mm<sup>3</sup>, and platelets 189,000 mm<sup>3</sup>. Blood biochemistry demonstrated the following values: alkaline phosphatase (ALP) 105 U/L, aspartate aminotransferase (AST) 113 U/L, alanine aminotransferase (ALT) 89.3 U/L, gamma-glutamyl transpeptidase (GGT) 120 U/L, total bilirubin 2.42 mg/dL, direct bilirubin 1.77 mg/dL, amylase 182 U/L, lipase 201 U/L, and C-reactive protein (CRP) 67.48 mg/L. In her abdominal ultrasonography, the thickness of the gallbladder wall was found to be normal, and a hyperechogenic lesion consistent with a gallbladder polyp of diameter 3 mm was observed inside the lumen. A linear hyperechogenic area was observed in the

Akyüz F, Çavuş, Kaymakolu S. A case of cholestasis caused by *Fasciola hepatica* diagnosed with endosonography: "Sometimes seeing might not be enough, watching is required" *Endoscopy Gastrointestinal* 2019;27:62-64.

DOI: 10.17940/endoskopi.631855

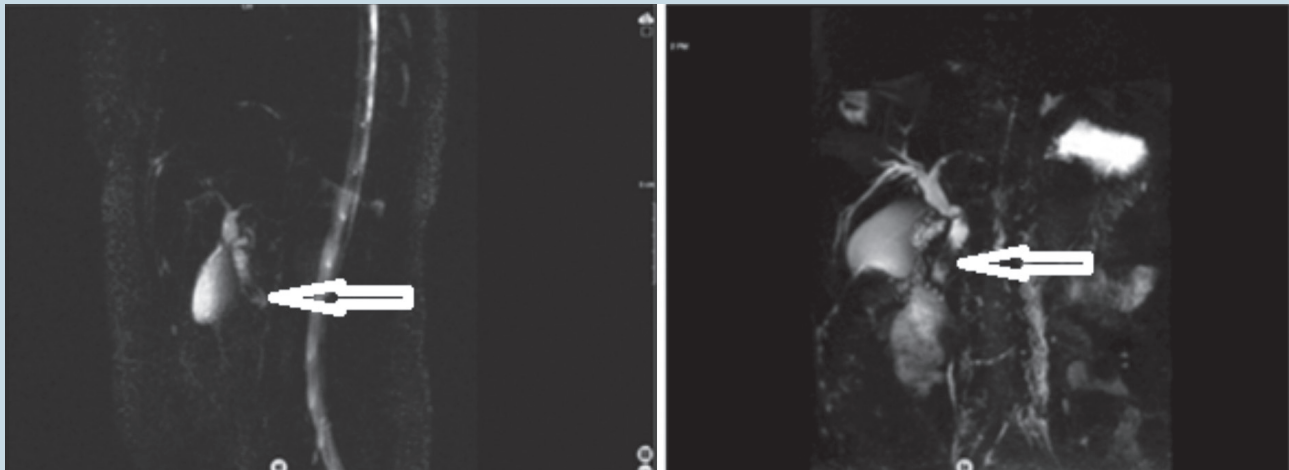
İletişim: Filiz AKYÜZ  
 İstanbul University İstanbul Medical Faculty  
 Department of Internal Medicine, Division of Gastroenterology  
 E-mail: filizakyuz@hotmail.com  
 Geliş Tarihi: 05.07.2019 Kabul Tarihi: 12.07.2019

gallbladder wall, and the diameter of the largest section was 5 mm. Magnetic resonance cholangiopancreatography (MRCP) revealed no pathology of the gallbladder. The diameter of the choledochus was 8 mm in the proximal section; a structure consistent with stenosis was observed in an approximately 1.5 cm segment of the midsection, and an area considered as mud was observed inside the lumen in the distal section of the choledochus in the foreground (Picture 1). The patient was later evaluated by endoscopic ultrasonography (EUS) examination performed in the bulbous with a linear probe, in which the size of the choledochus was found to be 1 cm in the distal section. The intrahepatic biliary tract was normal. The hyperechoic structure that was moving like a thin sheet inside the choledochus in the distal section was considered to be a parasitic lesion in the foreground (Picture 2 and Video 1). Afterward, endoscopic retrograde cholangiopancreatography (ERCP) was performed for the patient for treatment. After sphincterotomy that was performed in the ERCP, three

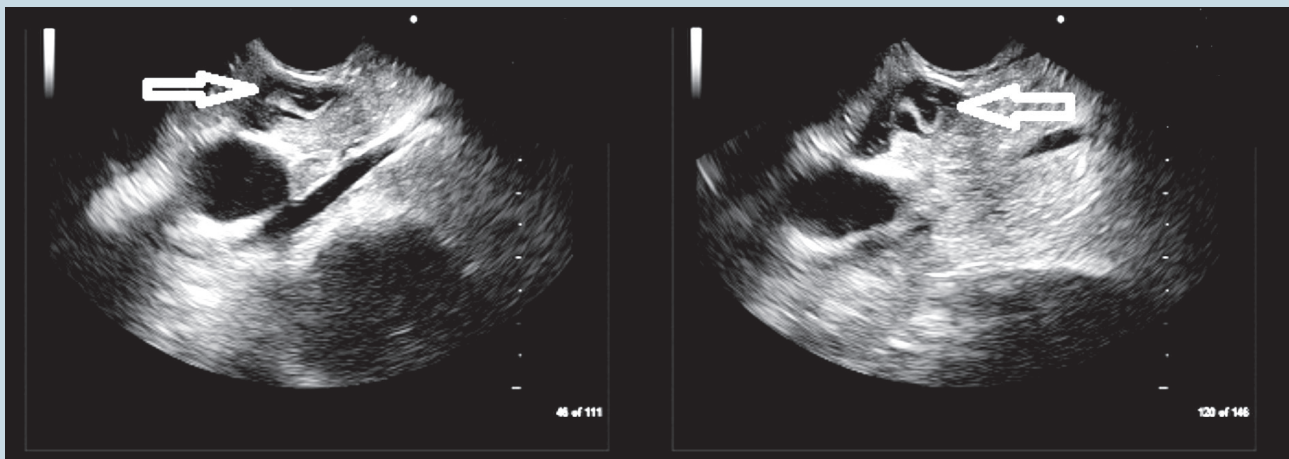
fasciola extractions were performed. Triclabendazole 10 mg/kg/day was administered to the patient as treatment, and the same dose was repeated after 24 hours. The patient's complaints regressed during the follow-up period.

## DISCUSSION

Fasciolosis, one of the parasitic diseases of the liver, is caused by the trematodes *F. hepatica* and *F. gigantica* (5). Human beings are a coincidental host for *F. hepatica* and are infected with metacercariae due to the consumption of contaminated water and food. The metacercariae lose their capsules, pass through the intestine wall and reach the abdominal cavity, and then penetrate the liver capsule and settle in the biliary tract. The acute and chronic stages of the disease are manifested by the changes that are observed during this migration of *F. hepatica* from the intestines to the liver and biliary tracts in the human body (5). Ultrasonography (USG), MRCP, and



**Picture 1.** Filling defect in the distal choledochus in MRCP.



**Picture 2.** EUS image of Fasciola hepatica in the distal choledochus.

ERCP are important for the diagnosis of the disease during the chronic stage, i.e., the biliary phase of the disease. The most recently published research states that EUS contributes to the diagnosis, particularly in the case of biliary fasciolosis. Moreover, among the abovementioned imaging techniques, EUS enables monitoring by providing continuity beyond re-

ording only sectional imaging, and therefore, it is superior to the other imaging techniques in the diagnosis of dynamic processes such as parasitic infections. In the diagnosis of fasciolosis, the disease should be suspected first in patients residing in endemic regions, after which appropriate imaging techniques should be applied.

## REFERENCES

1. Nyindo M, Lukumbagire AH. Fascioliasis: An ongoing zoonotic trematode infection. *BioMed Res Int* 2015;2015:786195.
2. Boşnak VK, Karaoğlu I, Sahin HH, et al. Evaluation of patients diagnosed with fascioliasis: A six-year experience at a university hospital in Turkey. *J Infect Dev Ctries* 2016;10:389-394.
3. Aminian K, Rezayat KA, Shafaghi A, Tanhaevash R. Living *Fasciola hepatica* in biliary tree: a case report. *Ann Hepatol* 2012;11:395-8.
4. Sarkari B, Ghobakhloo N, Moshfe A, Eilami O. Seroprevalence of human fasciolosis in a new-emerging focus of fasciolosis in Yasuj district, southwest of Iran. *Iran J Parasitol* 2012;7:15-20.
5. Cwiklinski K, O'Neill SM, Donnelly S, Dalton JP. Prospective view of animal and human fasciolosis. *Parasite Immunol* 2016;38:558-68.